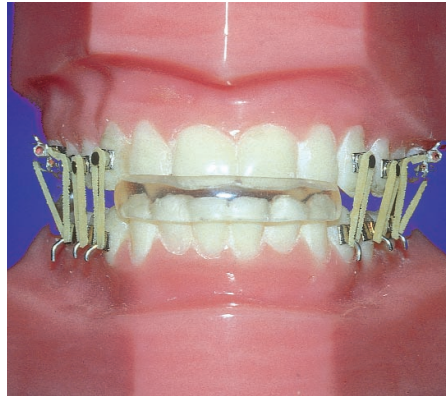
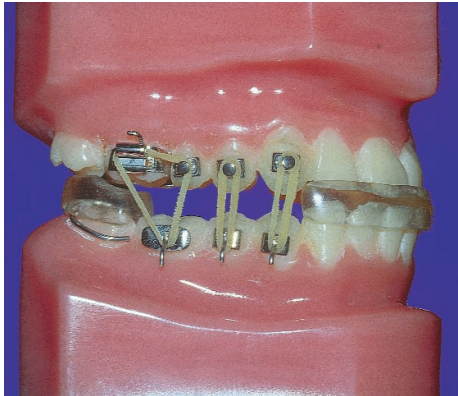


# THE SPAHL SPLIT VERTICAL ERUPTION ACCELERATION APPLIANCE SYSTEM



*The Spahl Split Vertical Eruption Acceleration Appliance System*

## INDICATIONS:

*Susan, an eighteen year old female patient is just coming out of Phase I mandibular advancement treatment with Clark Twin Blocks. Although her anterior incisors are coupling nicely, she still has a large posterior open bite. Unfortunately, Susan is leaving for college in five months. What is the best way to bring her posterior teeth into occlusion within the limited treatment time left?*

*Jeff, a fourteen year old male patient, is in the late stages of mandibular advancement therapy with a functional appliance such as an Orthopedic Corrector with the mandible nicely advanced. But with being in a school play, band practice, debate team practice, and a new girlfriend, he simply isn't wearing his appliance for a sufficient time each day to complete the eruption of his posterior teeth. How will you close his unresolved posterior open bite?*

*Your forty year old "TMJ" patient has successfully worn a pull forward chewing splint for a year eliminating severe headaches and recapturing the discs in the process. Upon removing the splint, the typical results are observed: The mandible cannot be forced back to its original pretreatment retruded position;*

*when the patient bites down a proper anterior overbite/overjet incisal relationship exists; but a large posterior open bite also now exists. The patient is decay free and has never had any back teeth filled. She does not want a large number of posterior crowns or an overlay removable partial denture to resolve the gap between the upper and lower posterior teeth. Because of the patient's age and the numerous social interactions required in her job, passively erupting the posteriors with prolonged 18-22 hour per day use of a functional appliance is not an option. How can you quickly close the posterior open bite while maintaining the patient's improved joint health?*

A bilateral posterior open bite frequently occurs as part of today's modern orthodontic/TMJ treatment plans involving any sort of mandibular advancement. The Spahl Split Vertical Eruption Acceleration Appliance System (SSV) is a practical, timely and effective multiple appliance technique. **It is designed solely for the closure of posterior open bites that occur subsequent to mandibular advancement procedures.**

Even under the best of circumstances involving a young growing patient who is very cooperative and diligent in wearing a functional appliance for the prescribed period each day, passive eruption of posterior teeth proceeds slowly, often taking

a year or more to complete in large posterior open bite cases. In many adult cases, it is nearly impossible to obtain adequate posterior open bite closure with passive eruption alone. In both situations, the Spahl Split Vertical Appliance (SSV) can help. **The advantage of the SSV system is that it gives the clinician the option of using active rather than passive forces to erupt posterior teeth and as a result, posterior open bites can be resolved rapidly.**

## DESCRIPTION:

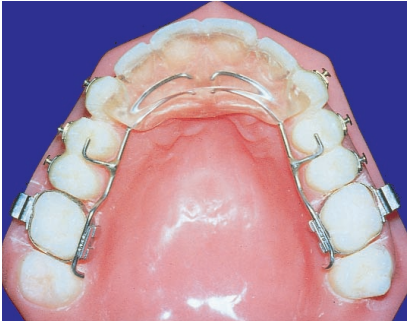There are three basic varieties of SSV; the Standard, the Second Molar and the First Molar variety.

1) The Standard SSV is a double appliance system that is used to erupt only the lower posteriors while leaving the upper posteriors in their original position. It consists of an upper bite plane behind the maxillary six anteriors held in by body wires from first (or second) molar bands; a lower removable night time mandibular fixation or positional appliance that properly aligns the upper and lower arches; and an active eruption complex consisting of bonded buttons on the upper posterior teeth, hooks or posted brackets on the lower posterior teeth and vertical elastics.

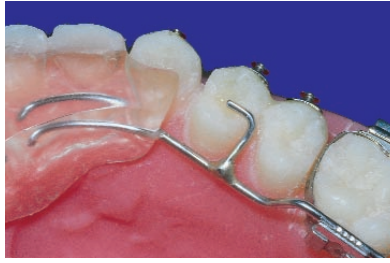
a. The upper bite plan (*figure 1*) is tucked about 1 mm under the incisal edges of the maxillary anteriors and stops distal to the cuspids. Its body wire (*figure 2*) fits flush against the lingual surfaces of the upper bicuspid at the height of contour and has a soldered wire occlusal stop on it engaging the distal marginal ridge of the upper first bicuspid. Rocky Mountain's Wilson™ lingual tube attachments (*figure 3*) are used so the bite plane can be removed for adjustment and hygiene purposes at regular office visits.

b. The lower removable night-only appliance (*figures 4 & 5*) consists of a cuspid to cuspid capped bite block with a lip on the cap extending up over the labial surfaces of the upper four anteriors. Its

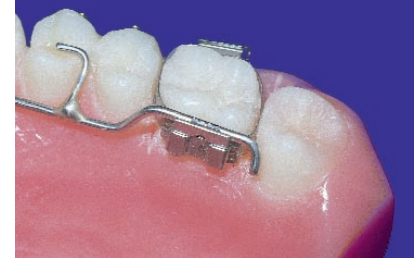## Components of the Spahl Split Vertical Appliance System



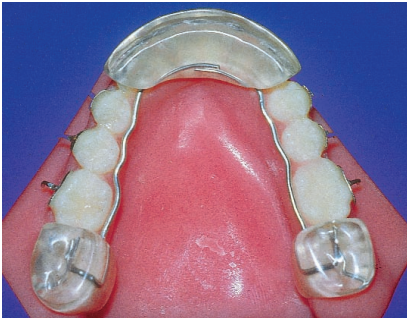(figure 1)



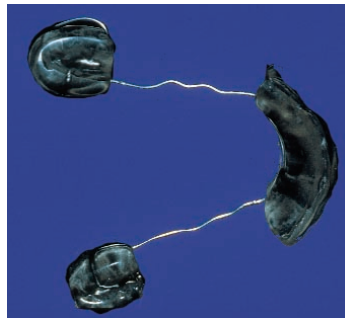
(figure 2)



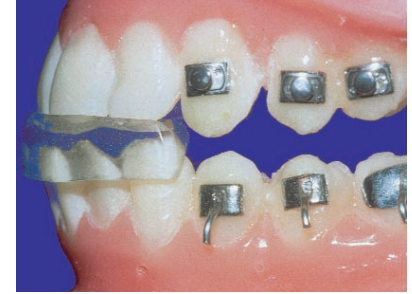(figure 3)



(figure 4)



(figure 5)



(figure 6)

body wire also fits flush against the lingual surfaces of the lower bicuspid and molars at their height of contour and runs posteriorly to bite blocks that sit on the occlusal surfaces of the lower second molars. When the patient inserts the appliance and bites on the anterior and posterior bite blocks, the upper and lower anteriors will be properly aligned and the posterior bite blocks will occlude with the upper first and second molars (figure 6).

c. With both appliances in place, vertical elastics are then applied to the bonded brackets, hooks, and buttons on the posterior teeth to apply eruptive forces. It is the exact placement of the body wires in the upper and lower appliances that allows the eruptive forces to occur without tipping these teeth lingually.

2) **The Second Molar variety, is used to erupt upper and lower posteriors towards each other reciprocally and simultaneously** (which also happens to speed bite closure). When reciprocal eruption is desired from the very start, the following modifications to the standard appliance design should be made:

a. The molar bands for the upper bite plane should be placed on the second molars instead of the first molars. This will prevent the cross arch transpalatal anchorage created by the bite plane appliance from locking up the eruption of the first molars.

b. Cut the wire stop off the upper first bicuspid.

c. Grind out the acrylic bite block free of the contact with the occlusal surface of the upper first molar (but not the upper 2nd molar).

3) **The First Molar variety is used when second molars are missing or are not yet present**, due to pathology or the mere fact that they have not yet erupted in the adolescent. An appliance is constructed similar to the standard SSV but with the bite blocks of the mandibular appliance resting on the first molars. It is used to erupt the bicuspid only (5x5). Once the bite is in full contact second bicuspid to second bicuspid and stabilized, the first molars are brought into contact vertically with each other by:

a. letting them erupt passively during the Bionator/OC1 retention phase of treatment.

b. erupting them actively with one vertical elastic per side during Bionator/OC1 retention phase.

c. erupting them actively with vertical elastics during the day counting on cuspal inclined plane action and a short interocclusal distance as a means of preventing lingual tipping.

d. cutting the acrylic bite blocks off the mandibular appliance, adjusting the body wire to support the lingual surface of the lower 1st molars and then using only one vertical elastic per side, molar to molar.

### TREATMENT:

1. As always, proper appliance selection and application requires a good diagnosis and treatment plan. It is recommended that the following records be taken:
  - Complete medical and dental history
  - Periodontal records
  - X-Rays (full series)
  - Cephalometric X-Ray and Analysis
  - Models
  - Photographs
2. Prior to using the SSV appliance system make sure that mandibular advancement has already been accomplished by means of a functional appliance such as a Bionator, Orthopedic Corrector I, Clark Twin Block, or some sort of "pull forward" TMJ splint.
3. Take an excellent set of alginate impressions and pour them up in yellow stone.
4. Take an appliance construction bite such that the anterior incisors are in an end to end relationship and between 2-4mm apart (figure 7). This will allow a lower appliance to be made that will hold the patient open 2-4mm beyond their ideal vertical relationship. This excess opening will allow the vertical elastics to have the proper force necessary to encourage eruption.
5. Make sure the upper anterior bite plane is made at the patients ideal vertical relationship. When this is done and the appliance is worn properly, the amount of the vertical eruption of the posteriors will be dictated by the height (or thickness) of this bite plane.



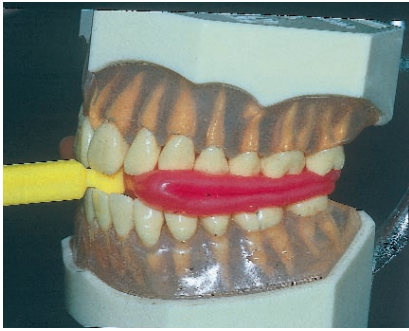


Figure 7: A proper construction bite taken with an Exact-o-Bite

6. Place separating elastics to create space for the band placement for the upper appliance.
7. Upon delivery of the appliance, try everything in before placing any brackets. Once you are satisfied that the appliance has been made to your specifications, go ahead and place the buttons and brackets on the posterior segments (Figure 8). Always use hooks or posted brackets on the lower posterior teeth. Because of the excessive angulation of the buccal surfaces of the lower posterior teeth, simple bonded buttons will often let the vertical elastics slip.




Figure 8: Proper placement of buttons and brackets

As the lower appliance is placed in the mouth and elastics engaged (**1/8 inch - 4 oz. medium**), the teeth are actively erupted. In the morning, upon appliance and elastic removal, as the patient bites down, the lower incisors occlude with the upper bite plane protecting the newly erupted posteriors from vertical re-intrusive type occlusal forces. Hence the speed of eruption.

8. The elastics (1/8 inch - 4 oz. medium) follow a 1:1, 1:1, 2:1 attachment formula (Figure 9). With the lower appliance in place holding the anterior incisors end to end about 2-4mm apart, the teeth align over each other such that the first elastic goes from upper cuspid to lower first bicuspid, the second elastic goes from upper first bicuspid to lower 2nd bicuspid, and the third elastic goes from both the upper 2nd bicuspid and first molar bracket down to the lower first molar.

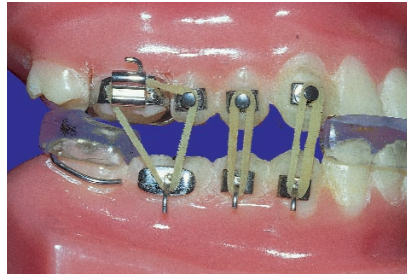


Figure 9: Proper elastic setup for eruption

9. In this initial configuration, the upper cuspid is stopped by the acrylic bite plane against its lingual surface, the upper first bicuspid is stopped by the soldered occlusal wire stop off the appliance body wire. The upper 2nd bicuspid is ligated with the elastic to the upper first molar. Together they are stopped by the occlusal contact of the distal portion of the upper first molar on the mesial edge of the posterior bite block of the mandibular appliance. This results in eruption of the mandibular bicuspids and first molars only. (Figure 9)
10. Second molars (which usually have the shortest distance to go anyway due to the Curve of Spee) are left to erupt passively on their own once treatment is complete. Alternately, second molars may be erupted with a singular vertical elastic per side during the Bionator retention phase of SSV treatment if active eruption of these teeth is desired.
11. Although the upper bite plane is worn 24 hours a day, the patient should be advised to wear the lower appliance and elastics no more than 10-12 hours per day usually during late evening hours and sleep. The bone and periodontal tissues need about 12 hours per day to "rest" free of traction forces, hence use of the appliance system with elastics more than 12 hours per day is contraindicated.
12. Because of the speed of eruption of the teeth, patients should be checked every two to three weeks. A 4mm. open bite can be closed in a matter of a few months.
13. In "powering" the posterior open bite shut, one posterior quadrant will often "come in" to occlusion before the other as most cases are asymmetrical vertically from one side of the arch to the other. Once bilateral full occlusion is obtained, at least another 2-4 months of active elastic usage (night only) is indicated to stabilize the bone in the sockets (even 4-6 months if the patient will cooperate).
14. Retention and active stabilization at the completion of posterior open bite closure is mandatory. This appliance system closes posterior open bites very rapidly but once the teeth are in contact and "over-

corrected", the bite plane should be left in place for several more months without the use of the night time appliance or elastics to insure that the eruption has stabilized and will hold. But upon removal of the bite plane, elastic attachment brackets, buttons, and hooks, the use of a Bionator retainer or an Orthopedic Corrector retainer (in an end to end construction bite 2-3mm. open interincisally) is mandatory. In children and adolescents, the final results are much more stable and 6-12 month retention with such an appliance as a Bionator/OC1 during sleep only is advisable. In adults, a much greater relapse potential exists. Therefore, Bionator/OC1 use during sleep may be needed for 3-5 years or possibly longer due to other complicating factors associated with certain adult mandibular advancement TMJ cases.

### CARE FOR THE APPLIANCE:

While the lower part of the appliance can be taken out for cleaning by the patient, the upper bite plane can only be removed by the dentist. Although hygiene can be difficult, cleaning underneath the bite plane after every meal is essential as food will tend to collect under the appliance. The use of a water pik is recommended to help maintain excellent oral hygiene. After its night time wear, the lower part of the appliance should be scrubbed thoroughly with a tooth brush and tooth paste, rinsed with cool water, then stored carefully in its storage case.

### CONTRA-INDICATIONS AND CONCERNS:

Remember, the SSV appliance system is not to be used as a mandibular advancement appliance. Its use is only indicated when orthopedic advancement, joint stabilization, arch form correction, and complete retraining of the "Class II neuromuscular sling" have all be accomplished by means of an overall comprehensive functional appliance treatment plan. Appliances may include the Bionator, Orthopedic Corrector I, Clark Twin Blocks, or some sort of "pull forward" chewing TMJ splint.

In the event the posterior open bite is 5mm or greater, a larger less powerful elastic is needed such as a 3/16, 4-oz. medium until the posterior teeth erupt close enough to permit use of the smaller more powerful 1/8 elastic. Too much elastic force causes the teeth to become excessively sore and may cause pulpal damage.

When the appliance is worn properly, over-eruption of posterior teeth will be impossible. Once the lower appliance is removed and the posterior teeth are allowed to make contact, occlusal forces will re-intrude any teeth that have over-erupted beyond the vertical height established by the anterior bite plane. In turn, intrusion is stopped by the braking action of the lower incisors striking the upper bite plane.

Do not use elastics without the mandibular appliance in place. The acrylic bite blocks of the posterior portion of the night time mandibular appliance are very important. They absorb the force vectors of the cumulative elastic traction on the entire mandible and are critical in preventing those forces from being transmitted to the joints. Without the lower appliance, wearing elastics for 10-12 hours per night could cause joint damage.

Upon insertion of the appliance, it is often necessary to instruct the patient to take common analgesics at bed time for the first several nights. There is often initial tenderness of the teeth and alveolar processes associated with the first week of appliance usage.

The use of separating elastics of any sort to facilitate initial eruption is not indicated. The teeth are not intended to be extruded out of their sockets, but rather the alveolus, gingival attachment, and gingival crest are stimulated en masse to develop vertically as a response to the cumulative forces of the elastics.

If reciprocal eruption of the uppers is desired (after a period of eruption of the lowers has been accomplished with a Standard SSV), it is possible to modify the Standard SSV into the Second molar variety by: 1) Cutting the wire stop off the upper first bicuspid; 2) Grinding out the acrylic bite block free of the contact of the occlusal surface of the upper first molar (but not the upper second molar); 3) Removing the upper bite plane via Wilson attachments and expand the body wire about 3-4mm transversely and re-insert. This stimulates the first molars to facilitate eruption and helps counteract the cross arch transpalatal anchorage of the bite plane that would resist eruptive forces. Because the acrylic bite plane is attached to the first molars, as they erupt, the front acrylic portion of the bite plane will lose its contact with the rugae of the premaxillary area. Remove the bite plane and adjust the body wire with bird beak pliers bending the acrylic portion back up against the rugae area. This will re-establish the firmness of contact.

**LAB REQUIREMENTS:**

- 1) Accurate upper and lower dental casts poured in yellow stone. Occlusal surfaces should be bubble-free.
- 2) An accurate construction bite:
  - a) The bite should register 2mm.-4mm. vertical clearance between the upper and lower incisors and the midlines should be aligned.
  - b) The anterior positioning of the mandible should bring the incisors edge-to-edge: assuming that there is not excessive upper anterior flaring and that this position is comfortable for the patient.
  - c) IT IS IMPORTANT TO CHECK THE COMPLETED CONSTRUCTION BITE

BY PLACING IT BACK ON THE WORKING MODELS. Check the bite for proper midline, AP, and vertical correction and then carefully wrap the bite separately for shipment.

3) A complete prescription. The SSV has three basic modifications. So it is very important to give the lab your exact specifications.

**SUPPLY LIST:**

- [ ] Sur-Wax
- [ ] Exacto Bites\*
- [ ] Water bath\*
- [ ] U-15 Scaler
- [ ] Acrylic burs\*
- [ ] Bird beak pliers\*
- [ ] 3 prong pliers\*
- [ ] Acid-etch bracket bonding kit\*
- [ ] Boley gauge\*
- [ ] Direct bond bracket removing pliers\*
- [ ] Molar band removing pliers\*
- [ ] Band biter\*
- [ ] Cotton plier or bracket placement tool\*
- [ ] Orthodontic band cement\*
- [ ] 3/16", 1/8" elastics - 4 ounce medium\*
- [ ] Extra high profile bondable buttons\*
- [ ] Bondable hooks\* or posted brackets\*
- [ ] Pumice
- [ ] Cheek retractors\*
- [ ] Acrylic repair kit\*
- [ ] Elastic or brass separators\*
- [ ] Impression trays\*, alginate\*, vibrator\*, dental stone
- [ ] Mixing bowls\* and plaster spatulas\*
- [ ] Plastic Elastic Applicators\*
- [ ] Composite finishing burs and discs

\* All available through Success Essentials products division of Space Maintainers Laboratory

**LAB FEES:**

The average laboratory fee runs approximately \$175-200. It includes the upper bite plane appliance on molar bands with Wilson™ removable lingual tube attachments, the lower night appliance, and a supply of appropriate sized elastics and plastic elastic applicators. It also includes the buttons for the upper teeth and the hooks or posted brackets for the lowers.

**INCOME POTENTIAL - THE ECONOMICS OF THE SSV SYSTEM:**

Since it is only used as a component to an overall full orthodontic/TMJ treatment plan, \$2500.00 to \$5500.00 per case is not unusual. The fee will of course depend upon the complexity of the case and whether or not finishing will require full arch bracketing.

Clearly the SSV "earns its keep." By virtue of the speed and positive orthodontic control, it lends to solving one of the most time consuming aspects of modern orthodontic care, i.e. the closure of large posterior open bites attendant to mandibular advancement procedures.

A study in the May '91 issue of The Journal of Clinical Orthodontics, pages 295-297, indicated that practices using functional appliances usually had a substantially higher gross income when compared to practices that do not offer this service to their patients.

Keep in mind the possibility of using the SSV System in conjunction with TMJ therapy for your adult patients. This may prove to be the most exciting development yet in TMJ treatment. We are just beginning to realize the potential of this dynamic appliance.

Written by: Dr. Terrence Spahl  
 Edited by: Dr. Rob Veis  
 Director of Practice Development

**REFERENCE:**

Spahl, T.J.: The Spahl Split Vertical Eruption Acceleration Appliance System. J Clinical Pediatric Dent Vol 18, No 2 1994, pp77-93

Spahl, T.J.: The Spahl Split Vertical Appliance. The Functional Orthodontist Vol 9:2 March 1992, pp27-33

Spahl, T.J.: The Spahl Split Vertical Appliance, Part II . The Functional Orthodontist Vol 9:3 May 1992, pp30-36

Spahl, T.J.: Case Study:The Spahl Split Vertical Eruption Acceleration System . The Functional Orthodontist Vol 10:1 January 1993, pp10-21pp

The Practice Building Bulletin is a special service of Space Maintainers Laboratory produced solely for the private use of our clients. It is designed to help expand and enhance your ability to provide comprehensive patient care. As an active client, you will continue to receive all future editions at no charge. Subscriptions are available for \$98.50 for 10 bulletins and includes a free three-ring binder with all back issues to date. Information included is the opinion of the author and may not be reproduced in any form without written consent.

SML Contact: 800-423-3270

Vol. II, Number 10 • Chatsworth, California  
 Copyright © 1996  
 Space Maintainers Laboratory